

Ball Therapy

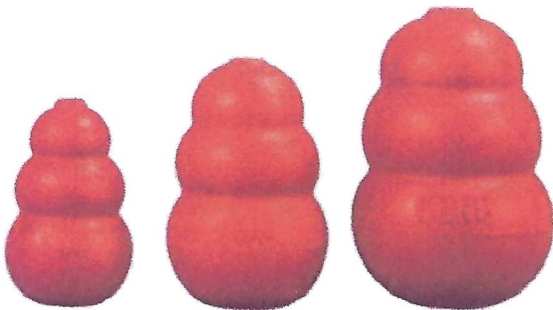
Here is a synopsis of a paper published in 1999.

A REMOVABLE ORTHODONTIC DEVICE FOR THE TREATMENT OF LINGUALLY DISPLACED MANDIBULAR CANINE TEETH IN YOUNG DOGS


Leen Verhaert, DVM

Summary: The malocclusion of lingually displaced mandibular canine teeth is a common orthodontic problem in the domestic dog. Several treatment methods have been described, and their advantages and disadvantages have been extensively reviewed. This article describes a functional technique used in 38 dogs of different breeds for correction of the malocclusion. The technique consists of stimulating the dog to play with specific toys. It is a simple, inexpensive, non-invasive technique that has a success rate comparable to conventional orthodontic techniques for treatment of this common malocclusion. *J Vet Dent* 16(2); 69-75, 1999.

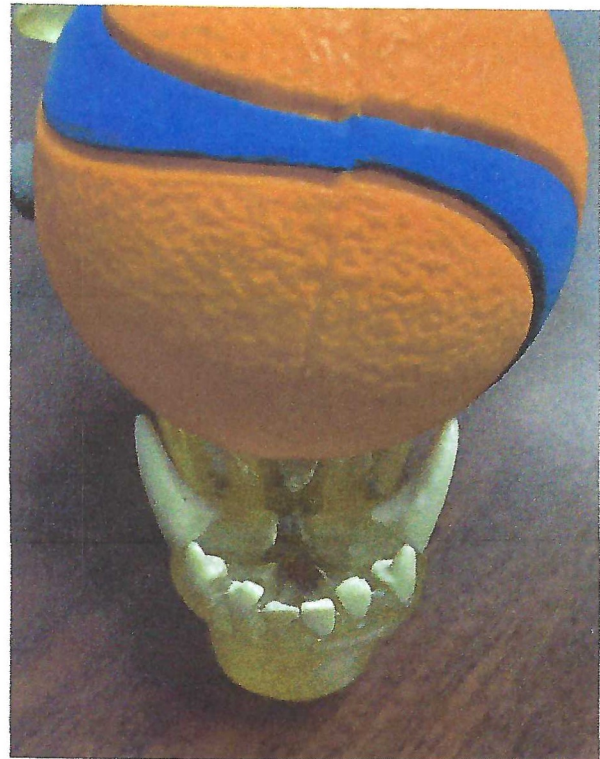
Here is my paper on [Malocclusions](#). Linguoversion (lingually displaced or base narrow mandibular canine teeth) when the jaw-length relationship is normal or when there is only a mild class II malocclusion (lower jaws too short compared to upper jaw) may sometimes be amenable to this very simple technique. It involves the use of a removable, passive-force orthodontic appliance in the form of an appropriately sized pliable ball toy or a Kong® Classic™ toy.



My current recommendation for the ball to use in this technique is the Chuckit® Ultra Ball. They are available in three sizes (small, medium and large) so you can get the size best suited to your pet. The photo top-right shows the desired size of the ball relative to the space between the lower canine teeth so that the ball is applying some gentle outward force on the tips of those teeth as it sits in that space.




Do not use tennis balls as the nylon fuzz is very abrasive and can cause serious dental wear.




The concept is amazingly simple. Have the owners encourage the dog to hold/carry the 'appliance' as much as possible, holding it in the mouth just behind the canine teeth. The presence of the ball will apply a gentle force on the lower canines out towards the lips and encourage these teeth to tip into proper position as they are erupting. In the picture above, the medium-sized Chuckit® ball is an appropriate fit for this model of a mouth.

In the next photo (top of page 2), we see the same model holding a small Chuckit® ball. This small ball is almost too small to apply the desired force on the canines and if it got to the back of the mouth (next photo), it could be a choking hazard.



Next we see the large Chuckit® ball in the model and it is too large. It sits too high on top of the lower canine tooth tips and would not apply the outward force we are looking for.



Here is a [Case Report](#) showing before and after images of a dog who responded well to Ball Therapy.

As with any intervention, case selection is important. Ball Therapy is really intended to help guide the eruption of the lower adult canine teeth in dogs whose jaw-length relationship is normal or close to it. It will not work for dogs with significant class II or class III malocclusions. I almost never recommend Ball Therapy for the primary (baby) teeth, preferring to extract those temporary teeth for various reasons.

For puppies who have had their lower primary canine teeth extracted because they were lingually displaced, I typically recommend starting to train the pup to play with balls about 7 to 14 days after the extractions (giving those wounds time to heal first). This may be well in advance of the eruption of the adult teeth but my thinking is that if the owners can train the dog to be playing with ball before the adult teeth start erupting then they are already doing it as soon as the adults start erupting and we get the maximum benefit from the activity.

The next best time to start this treatment is as soon as the adult canine teeth have broken through the gingiva and the primary canine teeth have exfoliated or been removed. Typically, this is around 5 to 5.5 months of age. It is far easier to encourage the erupting teeth to go where we want them to be than to

move teeth once they have finished erupting, so timing is important here.

Typically, puppies are seen at 8, 12 and 16 weeks for vaccines and then not again until 6 months for spay/neuter and so the best window of opportunity may be missed with this schedule. I always recommend that puppies also be examined at 5 months of age for a dental development evaluation. If, at this visit, there is concern that the mandibular canines are erupting base-narrow, a few weeks of ball therapy may just help the problem resolve without any further intervention.

I see no down-side to trying Ball Therapy in the right circumstances. There is no anesthetic involved, the appliance costs only a few dollars, the 'procedure' is painless and voluntary. So even if Ball Therapy does not work, at least it will do no harm. Also, even if Ball Therapy does not fix the occlusion, at least we now have a dog who has been trained to play with appropriate toys and that can have a life-long benefit.

Some tips on instituting Ball Therapy

Recently a client shared how she trained her pup to chew on his ball and gave me permission to share her technique. In this case, I had seen the pup at 9-weeks of age to remove the lingually displaced lower primary canine teeth and recommended ball therapy to be started as soon as those extraction sites had healed so the pup was well indoctrinated by the time the adult teeth started to erupt. Here is what the client did:

We played fetch with every meal and fed him spoonful by spoonful. This was working to have the ball in his mouth, but there was no chewing. So, I bought a Kong™ crackle ball and squeak ball to teach him to chew. Every time he made the ball squeak or crackle, I would mark and reward. Eventually, anytime he had a ball he would chomp, even with the hockey balls. So, we continued fetch for meals and put away all the other toys like you suggested.

This method worked very well, and the dog's lower adult canine teeth are now right where they should be. One of the keys to success here, I am quite convinced, is the early (8 to 10 weeks of age) removal of the displaced lower primary canine teeth combined with the ball therapy with training starting before the adult teeth have started to erupt. That gives us the best chance of a successful outcome.

As that owner alluded to, we recommend removing all toys from the environment and then filling the house with balls so the only toys available are the balls and they are all over the place so anytime the dog feels the need to have something in its mouth,

there is a ball close by. After the teeth have moved to their desired location, the pup can have its other (appropriate) toys back again.

While I am on the subject of toys, let me remind you of the [Kneecap Rule](#). Many things people give their dogs to chew and play with are very damaging to teeth (too hard, too abrasive or both). The Kneecap Rule states that if the object is hard enough to hurt your dog if you smacked them in the kneecap with it, then it is too hard to chew on. This would include natural bones, nylon bones, antlers, large raw hide, dried bull penises ("Bully Sticks"), dried cow hooves, ice cubes, rocks...

Even some soft toys are very damaging. Tennis ball and other toys covered with that material are very abrasive. The fuzz is abrasive itself. It also traps dirt/sand/grit and so now chewing on the toy is like chewing on sandpaper and can wear teeth down in a hurry.

So, we want pliable toys that are smooth(ish) and can be kept clean and free of grit.

Conclusion

Ball Therapy is a great technique for dogs with lingually displaced lower canine teeth and normal or near-normal jaw-length relationships.

Ball Therapy is intended to guide or shift the erupting lower adult canine teeth to desirable positions.

Ball Therapy is not for primary teeth. If the lower primary (baby) canine teeth are lingually displaced, they should be extracted ASAP to immediately alleviate the painful traumatic contacts and give the best chances for a successful outcome. Then, after healing of these extraction sites, Ball Therapy can be started to guide the eruption of the adult teeth.